

# Medical Microbiology

(Medical Parasitology)/ 2<sup>nd</sup> Semester

Faculty of Pharmacy/ 2<sup>nd</sup> Stage

**Lec..2 (Pathogenic and Opportunistic Free-living Amoebae)**

## Intestinal Protozoa

### Sarcodina (Amoebae)

#### *Entamoeba histolytica*

Morphology: the parasite exists in three forms; trophozoite, precyst and cyst. Trophozoites; 10-60  $\mu\text{m}$  size, unidirectional motility, single pseudopodium, ingest erythrocytes, granular cytoplasm small, central karyosome, and beaded chromatin. Only *Entamoeba histolytica* is of medical importance .

#### Habitat

Trophozoite of *E.histolytica* reside in mucosa and submucosa of large intestine of man.

#### Life cycle

It passes its life cycle in only one host. Cysts are passed in faeces. Man acquires the infection by ingestion of mature quadrinucleate cysts in faecally contaminated food or water. Trophozoites can also be passed in diarrhoeal stools, but are rapidly destroyed once outside the body, and if ingested would not survive exposure to the gastric environment. In contrast, cysts may remain viable in a humid environment and stay infective for several days. Flies and cockroaches can also serve as vectors for the transmission of *E. histolytica* cysts.

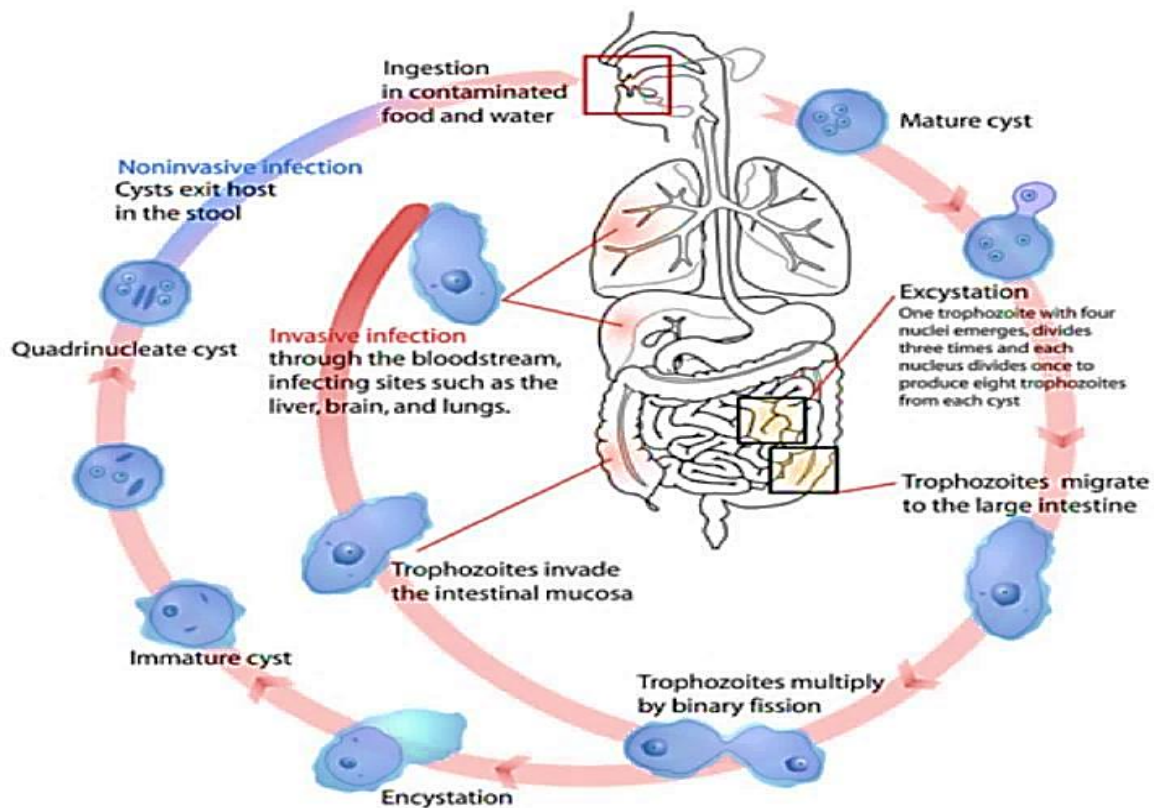
In the small intestine the cyst wall is lysed by Trypsin and a single tetranucleate amoeba (metacyst) is liberated. Each nucleus divides by binary fission giving rise to eight nuclei, thus from each mature cyst eight small metacystic trophozoites are produced. This process is known as **Excystation**.

Metacystic trophozoites are carried in the faecal stream into the caecum. They invade the mucosa and ultimately lodge in the submucous tissue of large intestine. Here they grow and multiply by binary fission. During growth, *E. histolytica* secretes a proteolytic enzyme which brings about destruction and necrosis of tissue and produces flask- shaped ulcers.

**Encystation:** occurs in the intestinal lumen in which chromatin materials are concentrated into bars (chromatoidal bodies) in the cytoplasm of the cyst. The nucleus of cyst divides into two, then each of the two daughter nuclei divided once

again so mature cyst has four nuclei. The amoebae are mostly present at the periphery of the lesion. A large number of trophozoites are excreted along with blood and mucus in the stool leading to amoebic dysentery. In a few cases, erosion of the large intestine may be so extensive that trophozoites gain entrance into the radicles of portal vein and are carried away to the liver where they multiply leading to amoebic hepatitis and amoebic liver abscess.

It has been established that the invasive and noninvasive forms represent two separate species, respectively *E. histolytica* and *E. dispar*. These two species are morphologically indistinguishable unless *E. histolytica* is observed with ingested red blood cells (erythrophagocytosis).



## Pathogenesis

**Intestinal amoebiasis:** After an incubation period of 1-4 weeks, the amoeba invade colonic mucosa. During growth, *E. histolytica* secretes proteolytic enzymes, producing flask-shaped ulcers and profuse bloody diarrhea (amoebic dysentery). Ulcers may be deep or superficial.

*E. histolytica* may also cause amoebic appendicitis and amoebomas (pseudotumoral lesions associated with necrosis, inflammation and oedema).

**Extraintestinal amoebiasis:** About 5-10% individuals with intestinal amoebiasis, 1-3 months after disappearance of dysentery, develop hepatic amoebiasis. Trophozoites are carried from the ulcer in the large intestine and multiply in the liver, lead to cytolytic action then small abscesses merge to form big liver abscesses. The abscesses may grow in various directions; it may enter into general circulation involving lungs, brain, spleen, skin, etc.

### **Pathogenicity depend on:**

1. Virulence of strain
2. Resistance of the host (depends on the innate immunity).
3. State of nutrition of the host.
4. Infection with other agents (free of other infections mean less susceptible to infection).
5. Some drugs may irritate the intestinal wall so irritated intestine is more susceptible to infection.
6. Bacterial flora (metabolic processes can enhance the invasiveness)

### **Symptoms**

Fever, chills, and diarrhea, sometimes bloody or white mucus and often with cramps. Some people may have only mild abdominal discomfort or no symptoms at all. Symptoms can start 2 or more weeks after infection.

### **Laboratory Diagnosis**

*Entamoeba histolytica* must be differentiated from other intestinal nonpathogenic amoebae. The nonpathogenic *Entamoeba dispar* is morphologically identical to *E. histolytica*, and differentiation must be based on isoenzymatic or immunologic analysis. Molecular methods are also useful in distinguishing between *E. histolytica* and *E. dispar*.

- Microscopic identification of cysts and trophozoites in the stool is the common method for diagnosing *E. histolytica*. This can be accomplished using wet mount and permanently stained preparations as Iodine or trichrome or by Flotation or Sedimentation method for stool samples.

-Blood examination: shows moderate leukocytosis.

-Serological tests: in later stages of invasive amoebiasis, antibodies appear. Tests include ELISA, IHA and IFA.

-Histology: trophozoites can be identified in aspirates or biopsy samples obtained during colonoscopy or surgery.

- Molecular methods: DNA probe and PCR.

## **Antiamoebic drugs**

### **Amoebicides with luminal action**

- Di-iodohydroxyquin
- Diloxanide furoate
- Paromomycin

### **Amoebicides effective in the liver, intestinal wall and other tissues**

- Emetine
- Dehydroemetine

### **Amoebicides effective only in the liver**

- Chloroquine

### **Amoebicides effective in both tissues and the intestinal lumen**

- Metronidazole
- Nitroimidazole

## Nonpathogenic amoebae:

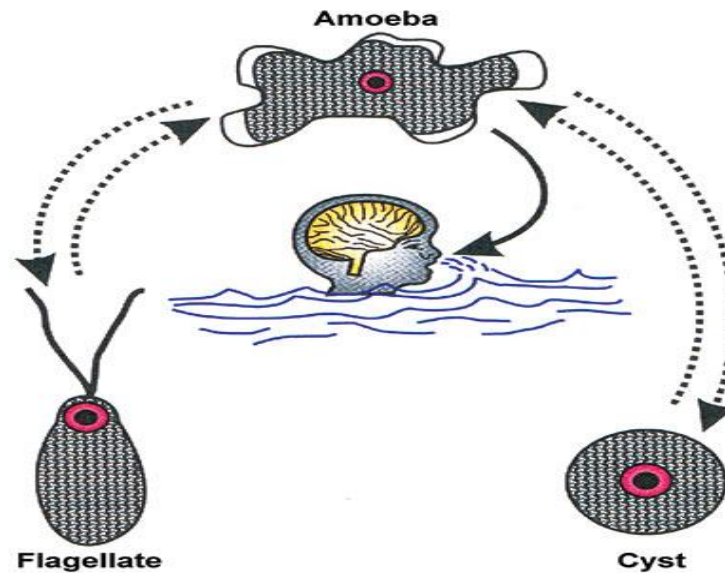
<i>Entamoeba dispar</i>	Morphologically identical to <i>E. histolytica</i> . It must be separated by isoenzymatic, immunologic or molecular analyses.
<i>Entamoeba hartmanni</i>	Some consider this a separate species. It differs from <i>E. histolytica</i> by being smaller in size.
<i>Entamoeba coli</i>	Distinguished from <i>E. histolytica</i> by having an eccentric endosome, and mature cysts with 8 nuclei. If chromatoidal bodies are present, they have splintered ends, rather than rounded as in <i>E. histolytica</i> .
<i>Endolimax nana</i>	This is a very small amoeba (6-15µm) with a large, eccentric endosome and thin nuclear envelope. Mature cysts contain 4 nuclei.
<i>Iodamoeba butschlii</i>	Both the trophozoite and cyst have one nucleus with a large endosome. The cyst contains a large glycogen vacuole that stains darkly with iodine, central karyosome and surrounded by refractile globules.

## Opportunistic amoebae

### *Naegleria fowleri*:

- *N. fowleri* has two stages: motile trophozoites and nonmotile cysts. The trophozoites occur in two forms: amoeboid and flagellate. Amoeboid form is elongate. It is actively motile by means of eruptive, blunt pseudopodia called lobopodia.
- It is a free-living amoeba that can be pathogenic, causing a fulminant brain infection called **naegleriasis**.
- Found in warm freshwater and in the soil near warm-water discharges of industrial plants, and in unchlorinated or minimally-chlorinated swimming pools.
- It can be seen in either an amoeboid or temporary flagellate stage. *N. fowleri* is inhaled through the nose, where it then enters the nasal and olfactory nerve tissue, travelling to the brain.
- *N. fowleri* normally eat bacteria, but when it enters humans, it uses the brain as a food source.

- It does not form a cyst in human tissue, where only the amoeboid trophozoite stage exists. Cysts and flagellate form of *N. fowleri* have never been found in tissues or cerebrospinal fluid(CSF).



### **Life cycle and pathogenicity**

The amoeboid form of *N. fowleri* is the invasive stage of the parasite. Man acquires infection by nasal contamination during swimming in freshwater lakes, ponds or swimming pools. Infection may also be acquired by inhalation of dust containing infective forms. It is likely that flagellate forms or cysts of *N. fowleri* could enter the nose. However, since the amoeboid form is the invasive stage of the parasite, therefore, it appears that flagellate forms revert to amoeboid forms and the amoeboid forms escape from the cysts in the nose.

The amoeboid forms invade the nasal mucosa, and travel along the olfactory nerves to brain leading to a rapidly fatal infection known as **Primary Amoebic Meningoencephalitis (PAM)**.

Patient develops severe frontal headache, fever (39°–40°C), anorexia, nausea, vomiting and signs of meningeal irritation. Involvement of the olfactory lobes may lead to disturbances in smell or taste. Patient may also develop visual disturbances, confusion, irritability, seizures and coma. The disease usually results in death within 72 hours of the onset of symptoms. The period between contact with the organism and onset of clinical symptoms vary from 2–3 days to as long as 7–15

days. PAM may resemble acute purulent bacterial meningitis, and these conditions may be difficult to differentiate particularly in the early stage.

### **Laboratory diagnosis**

Microscopy of CSF: Motile amoebae with characteristic morphology can be readily demonstrated in simple wet-mount preparation of fresh CSF specimen.

Culture: *N. fowleri* may be cultivated by placing some of the CSF on non-nutrient agar (1.5%) spread with a lawn of washed *Escherichia coli* or *Enterobacter aerogenes* and incubated at 37°C. The amoebae will grow on the moist agar surface and will use the bacteria as food, producing plaques as they clear the bacteria.

As colonies grow and expand, cysts that survive moderate desiccation are formed; thus, strains can be maintained by transfer of either trophic or cystic forms.

-Almost all cases are diagnosed during autopsies due to the rapid progression of the disease.

### **Treatment**

At present there is no satisfactory treatment for PAM. Antibacterial antibiotics and antiamoebic drugs are ineffective. Amphotericin B, a drug of considerable toxicity, is the antinaeplial agent for which there is evidence of clinical effectiveness